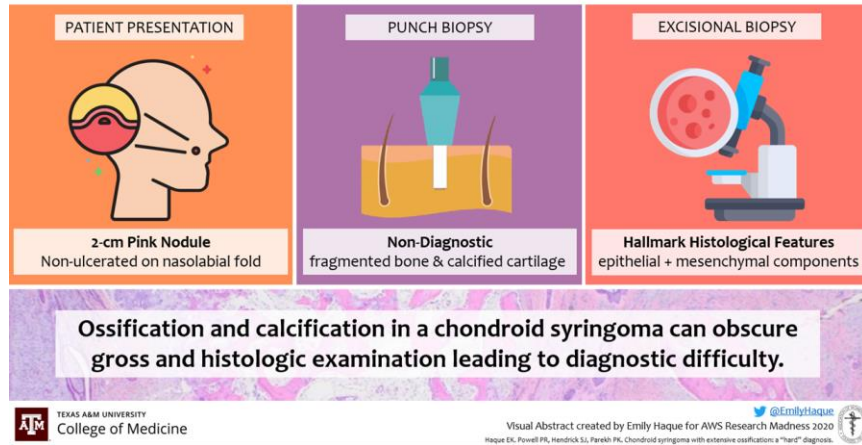


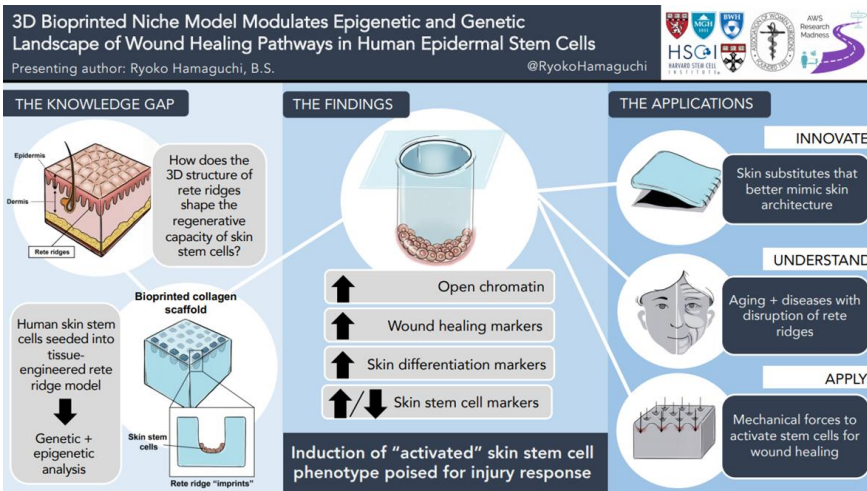
GROUP 32

71

Chondroid Syringoma with Extensive Ossification



72



73

Flap Necrosis with Apixaban after Mohs Surgery

CASE STUDY: A 93-yo woman undergoes MMS & cervico-facial flap reconstruction for BCC with continued apixaban, complicated by expanding hematoma, flap necrosis, and sepsis.

This case may demonstrate the need for alternative considerations in high-risk patients using direct oral anticoagulants when undergoing cutaneous surgery.

